



EFFICACY OF AGNIKARMA WITH SWARNA SHALAKA IN THE MANAGEMENT OF KARNINI YONIVYAPAD (CERVICAL EROSION) - A CASE REPORT

Manju Chouksey¹, Suresh Kumar Solanki², Hetal H. Dave³

¹Associate Professor, Department of Prasuti and StriRoga, L.N. Ayurved College and Hospital Bhopal, M.P, India

²Assistant Professor, Department of Prasuti and StriRoga, Ananya Ayurved College Kalol, Gandhinagar, Gujarat, India

³Associate Professor, Department of Prasuti and StriRoga, National Institute of Ayurved, Jaipur, Rajasthan, India

Corresponding Author: manjuchoksey23@gmail.com

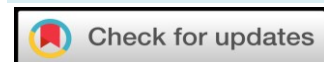<https://doi.org/10.46607/iamj.6208102020>

(Published online: October 2020)

Open Access

© International Ayurvedic Medical Journal, India 2020

Article Received: 05/10/2020 - Peer Reviewed: 08/10/2020 - Accepted for Publication: 11/10/2020



ABSTRACT

Nowadays Gynaecology OPD is full of cervical erosion patients, due to symptoms present in erosion are very much annoying. Erosion is the replacement of the stratified squamous epithelium of the ectocervix by the columnar epithelium of endocervix. The cervical erosion can be correlated with *Karnini Yonivyapad*. The case of cervical erosion was taken to evaluate the effect of *Agnikarma* with *Swarna Shalaka*. Present case study was undertaken in the OPD of Stree Roga and Prasuti Tantra Department L.N. Ayurved College and Hospital Bhopal, M.P. One sitting was given after 7th day of menstruation and the patients were followed up for two months. The effect of therapy was assessed on the basis of relief in signs and symptoms. The result shows that *Agnikarma* is an effective procedure for the management of cervical erosion, and *Swarna Shalaka* is a convenient medium having high efficacy in reliving the symptoms of erosion. So, this may be positively helpful in treating the cervical erosion.

Keywords: *Karnini*, Cervical erosion, *Agnikarma*, Swarna Shalaka.

INTRODUCTION

Clinically Cervical Erosion is the development of reddened area on the portio vaginalis around the external os. Pathologically, cervical erosion is a condition where squamous epithelium of the ectocervix (portio vaginalis) is replaced by columnar epithelium of the endocervix. It's interplay between two epithelia.

It's not an area denuded of epithelium as its name implies. It appears as red velvet like area on the ectocervix when visualized with speculum.

Cervical erosion is related to the hormone called estrogen and is common during pregnancy and in women on the contraceptive pills. If it is asymptomatic and physiological than needs no treatment, but when it is symptomatic and infected than the treatment is needed.

It is a common condition seen in most women of all the age groups. Its prevalence is more than 50% of all the gynaecological conditions¹. It is asymptomatic in initial stage but later on it progresses to show many symptoms like backache, white discharge, itching, painful coitus etc. It adversely affects the physiological & psychological health of women. It may even lead to infertility².

In modern system its treatment done with diathermy and cryosurgery which has various side effects like secondary infertility³, bleeding per vagina, infection, stenosis etc⁴. Cervical erosion may render the cervix mere susceptible to infection with various organisms like HPV, HIV¹, N. gonorrhoea, C. trachomatis, because the columnar epithelium has less power of resistance to infection than the normal stratified squamous covering.

The *Karnini Yonivyapad* described in Ayurvedic textbooks can be co-related with Cervical Erosion.

In Ayurveda *Kshara Karma* and *Agnikarma* are prescribed to treat the *Vrana*⁵, so the *Agnikarma* with *Swarna* is taken to destruct the ectopic columnar epithelium.

Need of The Study: 'Cervical Erosion' may not be hazardous, yet the chronicity of the disease and a number of symptoms both related to the genitourinary system as well as psychological imbalance in the patients affecting their daily routine. Bang *et al* in their study⁶ reported cervical erosion to be 45.70% presently 80-85% of women have been computed with cervical erosion. It is a benign condition but if left untreated may

leads up to infertility and predisposes cervical malignancy⁷. That's why it is important to pay attention towards this troublesome disease and to detect these lesions early enough and treat them adequately if cancer of the cervix is to be warded off⁸.

Aim: The aim of this Case Study is to highlight the efficacy of *Agnikarma* by *Swarna Shalaka* and Potential of Application of *Pichu* by the drug *Yashtimadhu Ghrita* in the management of the cervical erosion

Material and Methods: Informed written consent was taken from the patient in her own language and case was recorded as per Performa.

Case Report: A 36-year-old married women came in the OPD of SRPT Dept. of L.N. Ayurved College and Hospital Bhopal, M.P. with chief complaint of Thick white discharge per vagina since 2years. She also had mild irritation over vulva and mild pain in lower abdomen. Her menstrual history was regular and most recent began 4 days before. For this problem, patient took allopathic treatment, but disease recurrence was seen, and she was very disturbed in her daily routine activity that's why she came to OPD of *Srti Roga* Department of L.N. Ayurved College and Hospital Bhopal, M.P.

History of present illness: Her general health was good. There was no past history of sexually transmitted infection and OCPs. Presence of normal appetite. *Swedadhikya* (excessive sweating) occurred at working in hot or doing hard work. No *Tamodarshana* or faint was present.

History of past illness: Not significant.

Personal history:

- Diet – Vegetarian
- Appetite - Good
- Bowel - No constipation
- Micturation - 4-6 times/day
- Sleep - Sound sleep

Menstrual history: Has regular menstruation with duration of 5 days with the interval of 30days.

Obstetrical history: Had 3 children with FTND, age of last child being 6 years.

Ashtavidha Pareeksha:

- *Nadi* - 78 bpm
- *Mala* - twice a day

- Mootra - 4-6 times/day
- Jiwaha - Saam
- Shabda - Spashta
- Sparsha - Anushna
- Drika - Alpa Shwetabh
- Akriti - Madhyama

Dashavidha Pareeksha:

- Prakriti - Vata Kaphaja
- Vikriti - Kapha
- Sara - Madhyama
- Samhanana – Madhyama
- Pramana - Madhyama
- Satmya - Madhyama
- Satva - Madhyama
- Ahara Shakti – Madhyama
- Vyayama Shakti – madhyam
- Vaya - Yuvana

General examination:

- Built - Moderate
- Nourishment – Moderate
- Temperature - 98. 6 F
- Respiratory rate – 16 / min
- Pulse rate - 78 / min
- BP - 120/80 mm of HG
- Weight - 68 kg
- Tongue - Coated

Systemic examination:

- CVS - S1, S2 heard
- RS - normal breathing
- CNS - conscious, well oriented

Per Abdomen: soft, liver and spleen not palpable.

Per Speculum Examination – Per speculum Examination revealed thick white discharge and erosion was present both the lips of cervix. Vaginal wall was normal and oozing of blood on rubbing with gauze piece was present.

Per Vaginal Examination- Per Vaginal Examination revealed that uterus was anteverted- anteflexed, normal in size and non-tender in mobility. Cervix was downward direction, normal in size and shape, gritty on touch and both the fornices were free.

As per examination the case was confirmed of cervical erosion some investigations were carried out.

Investigation:

Complete Blood picture – Within normal limit

HIV, HBsAg, VDRL- Negative.

Urine for Routine and microscopy- Normal

Ultra-Sonography for Uterus and adnexae- Normal study

Pap's smear- Mild inflammatory

Informed Consent:

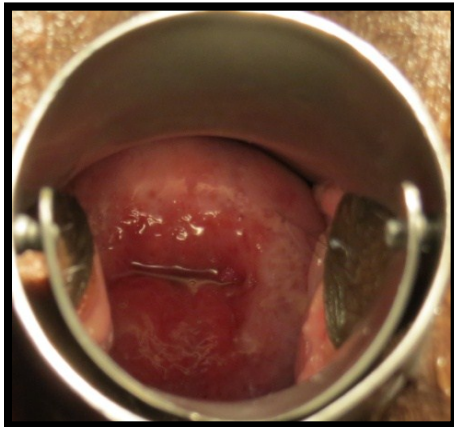
The purpose of the study, nature of the study drugs, the procedures to be carried out and the potential risks and benefits were explained to the patients in details in non-technical terms and trilingual. Thereafter their written consent was taken before starting the procedure.

Treatment protocol followed in the patient-

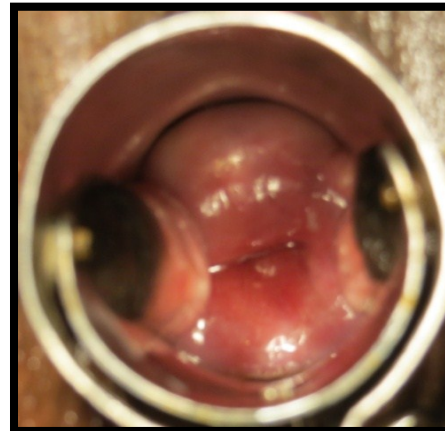
Patient was called on 2nd day after the Bleeding phase of the menstrual cycle (5th day from LMP). After urination patient kept in lithotomic position and Vaginal cleaning was done with savlon solution. Cervix was exposed with Cusco's speculum and cervix was cleaned properly. *Swarna Shalaka* was applied linearly on eroded area after being hot up to 5 minutes on gas burner. After Application of *Agnikarma*, *Pichu* (a piece of cotton wrapped gauze and tied with thread)) soaked with *Yashtimadhu Ghrita* was kept deep inside the vagina for 4 - 6 hours. It was kept close to the cervix in such a way that some length of thread remained outside of the vagina. Patient was explained well to remove the pichu by holding this thread. *Agnikarma* was applied for 1 sitting and '*Yashtimadhu Ghrita Pichu* applied for 14 days daily two times in a day.

Don'ts- Abstinence from sex was advised for the present cycle.

BT



AT



Result-

The assessment was done in every 7 days and final assessment done after the next cycle. There was improvement in sign & symptoms. White discharge firstly increased than after decreased up to 50 %, *Dourbalaya*, *Kati Shoola*, *Udara Shoola*, were reduced up to 50 %, while *Yonidorgandhya* was completely resolved. P/S examination showed the normal and healthy grown squamous epithelium on eroded area.

DISCUSSION

Cervical Erosion is chiefly the disease of reproductive age group and is commonly seen in sexually active females. Due to trauma in the cervix in previous deliveries and hyperplasia of cervical glands erosion occurs. The cases of mild or moderate erosions may revert back to normal and these are most often related to infection but some, however, either remain static or progress to CIN I, II or III. CIN III, however, is more susceptible to progress into invasive carcinoma. The treatment modalities in modern science are Cryotherapy, Cold coagulation, electro diathermy, laser vaporization, Large loop (electrosurgical) excision of transformation zone. This treatment costs a lot & causes side effects also like cervical stenosis, infertility, destruction of the healthy tissues. etc. Ayurvedic treatment modalities can be helpful in preventing or reverting back the progress of mild or moderate dysplasia to the advance stages. *Agnikarma* destroys the columnar epithelium & the squamous epithelium (pinkish tissue) grows on the eroded part, hence cervix looks healthy. *Agnikarama* can be

done by *Shalakas* which are made up of different metals like *Panchadhatu* etc but in this report *Swarna Shalakas* is used as *Swarana* has *Tridosahara*, *Vishapaham*, *Bruhaniya*, *Vranaghna*, *Lekhana* and *Vishnashana* properties. Gold compounds have a great potential for cancer treatment. During the last two decades, gold compounds are reported to possess relevant anti proliferative properties in vitro against selected human tumour cell

The classical drug '*Yashtimadhu Ghrita*' is one of the best drugs of Ayurveda, advised for local application in the management of *Vrana*. *Acharya Sushruta*⁹ has described (Su.Chi. 1/78-81) that use of this *Ghrita* cures the *Vrana* associated with excessive *Vedana*. Describing the effectiveness of this *Ghrita*, *Acharya* mentions that with the use of this finally wound is healed by virtue of its *Shodhana* and *Ropana* properties.

The goal of any therapy should be to reduce symptoms, improving quality of life, prevent complication and side effects of that particular therapy. Hence the *Ayurvedic* management seems to be more practical, effective, non-surgical and have negligible side effects.

CONCLUSION

Hence in this case we can concluded that *Bahirparimarjana Chikitsa* in the form of *Agnikarma with Swarna Shalaka* and *Yashtimadhu Ghrita Pichu* is highly effective in disintegration of the pathogenesis of the disease. Re-epithelisation occurs earlier, and no side effect or complications was found with the use of this treatment., it became more effective in removing

of nabothian follicles and managing the associated chronic cervicitis. Comparing the symptomatic improvement, it was found that overall relief in vaginal Discharge, Pruritus vulvae was seen well. The treatment was safe economic, non-surgical, very effective and can be used for the treatment of cervical erosion.

REFERENCES

1. www.bbb110.cn/health/com
2. Vaclav insler & Bruno lunenfeld. Infertility Male & Female Churchill Living Stone. Diagnosis & Classification of sperm – mucus interaction; edition 1993: pg no .345
3. D.C. Dutta, Benign lesions of the cervix in Textbook of Gynaecology including contraception, New Central Book Agency (P)Ltd. 6 th edition,2008; reprint 2009: pg. no.250
4. D.C. Dutta, Benign lesions of the cervix in Textbook of Gynaecology including contraception, New Central Book Agency (P)Ltd. 6 th edition;2008 reprint2009: pg. no.250
5. Sushruta, Sushruta Samhita of Mahrshi Sushruta. edited with Ayurveda-Tattva-Sandipika Hindi Commentary. scientific analysis. notes etc. by Kaviraja Ambikadutta Shastri. Publisher Chaukhambha Bharti Academy Varansi. Reprint; edition 2006: Sutra Sthana11/13
6. Bang RA, Bang AT, Baitule M, Choudhary Y, Sarmukaddam S Tale O. High prevalence of gynecological disease in rural Indian women. Lancet 1989; 1:85-7
7. Jeffcoate's Principles of Gynecology. JAYPEE Publication. revised and updated by pratapkumar andnarendra Malhotra. seventh edition; 2008: ISBN 978-81-8448-288-1
8. Gulati N, Chandra K. Clinicocytological study of benign cervical lesions. J Obs. Gynec India. 1973; 23:347-9.
9. Susruta Samhita. Chikitsa sthan. Commented By Shastri Kaviraj Ambika Dutta. Published by Chaukhambha Bharti Academy. Varanasi, Reprint Year 2010; Vol 2.

Source of Support: Nil

Conflict of Interest: None Declared

How to cite this URL: Manju Chouksey et al: Efficacy Of Agnikarma With Swarna Shalaka In The Management Of Karnini Yonivyapad (Cervical Erosion) - A Case Report. International Ayurvedic Medical Journal {online} 2020 {cited October, 2020} Available from: http://www.iamj.in/posts/images/upload/4934_4938.pdf